

## The ameliorative effect of ozone therapy on spinal cord ischemia in rabbits

The ameliorative effect of ozone therapy

Tarik Akman<sup>1</sup>, Adem Bozkurt Aras<sup>1</sup>, Tuncer Şimşek<sup>2</sup>, Müşerref Hilal Şehitoğlu<sup>3</sup>, Yasemin Yüksel<sup>4</sup>, Esra Aslan<sup>5</sup>, Canan Akman<sup>6</sup><sup>1</sup>Department of Neurosurgery, Canakkale 18 March University School of Medicine, Canakkale,<sup>2</sup>Department of Anesthesia and Reanimation, Canakkale 18 March University School of Medicine, Canakkale,<sup>3</sup>Department of Medical Biochemistry, Canakkale 18 March University School of Medicine, Canakkale,<sup>4</sup>Department of Histology and Embryology, Ankara Zekai Tahir Burak Women Health Education and Research Hospital, Ankara,<sup>5</sup>Department of Histology and Embryology, Afyon Kocatepe University School of Medicine, Afyon,<sup>6</sup>Department of First Aid and Emergency, Canakkale 18 March University School of Medicine, Canakkale, Turkey

### Abstract

**Aim:** Research in applications of O<sub>3</sub> treatment for spinal cord ischemia is a rich area of study. The effects of O<sub>3</sub> treatment on spinal cord ischemia have not been studied much to date. The aim of this study is to investigate the role of prophylactic administration of O<sub>3</sub> on the recovery of ischemic changes in terms of oxidative stress markers in lysosomal and mitochondrial enzymatic activities in the spinal cord of male rabbits. **Material and Method:** Twenty-four New Zealand White (NZW) adult male rabbits (weight: 2.5-3 kg) were obtained from Saki Yenilli Experimental Animals Center (Ankara, Turkey). The rabbits were housed in plastic cages at a temperature of 21 ± 2 °C, with 12 hours light/12 hours dark cyclus, fed with standard rabbit diet (Bil-Yem Ltd. Co., Ankara, Turkey) and water ad libitum for the duration of the experiment. Rabbits were randomly divided into 4 groups of 6 rabbits. The first group was accepted as control and the second group was treated with 50 µg/mL (20 mL) ozone by rectal insufflation 5 times per day. On the 10th day, animals were sacrificed. The third sham group had infrarenal abdominal aorta cross-clamping (IAACC) performed and were sacrificed 24 hours later. The fourth group was treated with 50 µg/mL ozone (20 mL) by rectal insufflation 5 times per day and on the 10th day, IAACC was performed. Twenty-four hours later the animals were sacrificed. **Results:** When data obtained from the biochemical analysis were investigated (Table 1) in the groups with induced ischemia, the expected reduction in SOD, CAT, and GPX enzyme activities was observed and an increase in MPO activity was observed. The statistical difference between ozone administered groups and the control group was significant ( $p < 0.05$ ). When the ischemia+ozone group is compared with the ischemia group, the results are significant and a statistical difference is observed ( $p < 0.05$ ). When GPX values in the group with ischemia-induced were investigated, the enzyme activity values were very low. A serious increase was observed in the ozone administered treatment group ( $p < 0.05$ ). **Discussion:** Ozone (O<sub>3</sub>) is a molecule carrying three oxygen atoms forming as a result of exposure of oxygen to high energy electric currents and ultraviolet (UV) light in nature. It is found as a gas at room temperature. It is colorless, and has a characteristic smell. As ozone has a high degree of oxidation strength, it is called "active oxygen" in medicine. Due to its ability to increase blood circulation, it is used for treatment, not just of disorders related to circulation, but as an aid to the renewal of organic functions disrupted by many diseases.

### Keywords

Ozone; Oxidative Stress; Ischemia; Spinal Cord

DOI: 10.4328/ACAM.6215 Received: 20.02.2019 Accepted: 11.03.2019 Published Online: 27.03.2019 Printed: 01.05.2020 Ann Clin Anal Med 2020;11(3):221-226

Corresponding Author: Tarik Akman, Department of Neurosurgery, Faculty of Medicine, Canakkale Onsekiz Mart University, Canakkale, Turkey.

GSM: +905322150627 F.: +90 2862635956 E-Mail: tarikakman@comu.edu.tr

ORCID ID: <https://orcid.org/0000-0001-7569-5845>

## Introduction

In situations with chronic oxidative stress, increasing endogenous oxidant capacity is more effective than removing exogenous antioxidants. Ozone (O<sub>3</sub>) treatment reverses chronic oxidative stress by regulating the changed cellular redox balance and succeeds through the production of messengers reaching all cells in the body. These messengers may stimulate the bone marrow to produce excess erythrocytes increasing the distribution capacity of O<sub>2</sub> in tissues. Thus, both antioxidant defense is increased and pentose phosphate and glycolysis pathways are activated. Additionally, these messengers may stimulate the release of stem cells from bone marrow for regeneration of ischemic organs [1].

Therapeutic ratios of ozone with 10-80 µg/mL dose interval created no side effects, additionally, it was reported that there were no negative effects on either erythrocyte or leukocyte functions [2].

Studies have shown that ozone normalizes organic peroxide levels preventing oxidative stress. As ozone has a high degree of oxidation strength, it is called "active oxygen" in medicine. O<sub>3</sub> treatment is a complementary medical approach, used in a wide disease group including neurodegenerative and vascular diseases, orthopedic pathologies and resistant infections [3].

O<sub>3</sub> therapy has been used as a complementary medical approach for years and has been used for a wide range of diseases including neurodegenerative diseases, vascular diseases, orthopedic pathologies and resistant infections [4,5].

Autonomic, endocrine, metabolic and immunological responses to harmful stimuli aiming to provide and sustain homeostasis of the body may be assessed as stress responses. Neutrophils activated by tissue destruction release some enzymes such as myeloperoxidase, acid phosphatase, and elastase. During the inflammatory response, there are changes in the ratio of leukocytes in circulation. Hypoxia occurring in situations of spinal cord ischemia may be seen biochemically due to acidosis, free radical damage and membrane disruption [6,7].

Recent studies have shown that in normal organisms, ozone has anti-inflammatory properties and increases the oxygen carrying capacity of hemoglobin [8].

Together with this, the use of O<sub>3</sub> treatment in spinal cord ischemia is still an area for research. According to our knowledge, the effects of O<sub>3</sub> treatment on spinal cord ischemia have not been researched yet. Additionally, the aim of this study is to reveal the role of prophylactic administration of O<sub>3</sub> on the healing of ischemic changes in lysosomal and mitochondrial enzymatic activities and also oxidative stress markers in the spinal cord of male rabbits.

Within the scope of our study, we aimed to research how ozone administered by rectal insufflation under general anesthesia to rabbits affected superoxide dismutase (SOD), catalase (CAT), glutathione peroxidase (GPX), myeloperoxidase (MPO) activities and malondialdehyde (MDA) levels.

In addition to, tissue healing was evaluated histopathologically and immunohistochemically. It is considered that the obtained data will produce findings beneficial to humans.

## Material and Methods

### Animals

Twenty- four New Zealand White (NZW) adult male rabbits (weight: 2.5-3 kg) were obtained from Saki Yenilli Experimental Animals Center (Ankara, Turkey). The rabbits were housed in plastic cages at a temperature of 21 ± 2 °C, with 12 hours

light/12 hours dark cyclis, fed with standard rabbit diet (Bil-Yem Ltd. Co., Ankara, Turkey) and water ad libitum for the duration of the experiment. Experiments were completed in accordance with authorization and instructions of COMU Animal Ethics Committee.

Rabbits were randomly divided into 4 groups of 6 rabbits. The first group was accepted as control and the second group was treated with 50 µg/mL (20 mL) ozone by rectal insufflation 5 times per day. On the 10th day, animals were sacrificed. The third sham group had infrarenal abdominal aorta cross-clamping (IAACC) performed and were sacrificed 24 hours later. The fourth group was treated with 50 µg/mL ozone (20 mL) by rectal insufflation 5 times per day and on the 10th day, IAACC was performed. Twenty- four hours later the animals were sacrificed.

### Surgical method

Before beginning the study, all experimental animals were given 10 mg/kg ketamine intramuscularly for premedication. Later, a 26 G vein catheter was inserted after a 24 G arterial catheter. For anesthesia induction, 2 mg/kg ketamine, 1 µg/kg fentanyl and 0.5 mg/kg rocuronium bromide were administered and after sufficient muscle relaxation was ensured, all animal had supratracheal intubation (V-gel rabbit) performed for airway reliability. During the anesthesia and surgical procedures, 1 % isoflurane and 50/50 % oxygen/air mix were administered for anesthetic maintenance. Rabbits were monitored with arterial monitoring and blood gas.

A temperature probe was inserted in the rectum. The surgical approach was in a supine position. After sterile preparation of the operation field, laparotomy was performed with a standard midline incision. After the intestines were moved to the side, the retroperitoneum was opened and the abdominal aorta was reached. The abdominal aorta was cross-clamped in 2 places: distal of the left renal artery and proximal of the aortic bifurcation. Loss of aortic pulsation was confirmed by palpation. The duration of ischemia lasted up to 45 minutes, and then the cross-clamp was removed and reperfused for 15 minutes. After removing the cross-clamp, distal perfusion was visually observed. A Biopac MP 36 (BIOPAC Systems, Inc. Goleta, CA, USA) device was used for monitoring. During the surgical procedure, mean arterial pulse was held at 250-300/minute. Body temperature was monitored with a rectal probe and held from 37.1 - 37.4 °C with a heating pad. After the procedure, the abdominal wall was closed with 3-0 prolene sutures. To sacrifice the rabbits, 1 mg/kg rocuronium intravenous (IV), 10 mg/kg ketamine IV, and 2 µg/kg fentanyl IV were used. The spinal cord from thoracic (Th) 6 to lumbar (L) 3 was rapidly removed with a posterior approach. Each spinal cord was longitudinally divided into two equal pieces with a thin scalpel. The half of the specimens taken for histopathological investigation were fixated in formalin for 7 days. The other half was stored in a freezer at -80 °C for biochemical investigations.

### Biochemical Analysis of Rabbit Spinal Cord Tissue

Immediately after tissues were removed, they were stored at -80 °C. For each method of biochemical analysis applied, tissues were separately prepared in appropriate buffer environments, homogenized and supernatants were obtained. Superoxide dismutase (SOD), catalase (CAT), glutathione peroxidase (GPX), myeloperoxidase (MPO) activity and malondialdehyde (MDA) levels were measured with very sensitive ELISA spectrophotometry. Studies were repeated twice. Total protein concen-

trations were found in accordance with the Bradford method (Sigma Aldrich, Bradford reagent-B6916-1KT, USA). All results were determined as the mean  $\pm$  standard deviations for each mg protein.

#### **Superoxide Dismutase (SOD) Activity**

Superoxide dismutase is an antioxidant enzyme catalyzing the transformation of superoxide free radicals ( $O_2^{\cdot-}$ ) to hydrogen peroxide ( $H_2O_2$ ) and molecular oxygen ( $O_2$ ). SOD activity IC50 (50 % inhibition of SOD activity) values were colorimetrically determined at 450 nm using an SOD assay kit (Sigma-Aldrich-19160-St.Louis, MO, USA). Results are given as U/ml per mg protein (U.ml<sup>-1</sup>.mg protein<sup>-1</sup>).

#### **Catalase (CAT) Activity**

Catalase is a heme protein with four of each group in its structure. It is an antioxidant enzyme that degrades hydrogen peroxide ( $H_2O_2$ ) to water and oxygen. CAT activity in rabbit brain tissues was determined with a trade kit STA-341, Colorimetric Cell Biolabs' Oxiselect™ Catalase Activity Assay Kit. Results obtained by ELISA spectrophotometry are given as U/ml per mg protein.

#### **Glutathione Peroxidase (GSH-Px; GPX) Activity**

Glutathione peroxidase is the enzyme responsible for the reduction of hydroperoxides. Glutathione peroxidase (GP) is found in mammalian cells and aids in preventing lipid peroxidation of cell membranes in free peroxide recipient cells. Glutathione peroxidase activity in brain tissue was determined with ELISA spectrophotometry using a trade kit ENZO, ADI-900-158, Glutathione Peroxidase Activity Kit. Results are given as U/ml per mg protein.

#### **Myeloperoxidase (MPO) Activity**

Myeloperoxidase (MPO) is a heme protein abundantly released by activated neutrophils and monocytes. Amounts increase during inflammation. When reactive oxidation products cause tissue damage, MPO activity increases. To determine the myeloperoxidase activity in rabbit brains, a STA-803, Cell Biolabs' OxiSelect™ Myeloperoxidase Chlorination Activity Assay Kit (Colorimetric) was used. Results obtained using ELISA spectrophotometry are stated as U/ml per mg protein.

#### **Determination of Lipid Peroxidation, Malondialdehyde (MDA) Levels**

Lipid peroxidation is determined by measuring color intensity at 532 nm of the product formed by the reaction of malondialdehyde (MDA) and thiobarbituric acid (TBA). In our study, to determine MDA levels a trade kit STA-330, Cell Biolabs' OxiSelect™ TBARS Assay Kit (MDA Quantitation) was used. Results are given as  $\mu$ mole/ ml per mg protein ( $\mu$ mole/ mL<sup>-1</sup>.mg protein<sup>-1</sup>).

#### **Histopathological Investigation**

The spinal cord used for histopathological investigation was placed in 10 % neutral formalin. Tissues were stained with hematoxylin-eosin and toluidine blue and general histopathological assessment was performed.

Caspase 3 plays a central role in apoptosis. The irreversible step of apoptosis is an activated caspase species. In the study, spinal cord specimens stained with caspase 3 antibodies aimed to determine changes belonging to apoptotic cell death.

Neuronal NOS (nNOS) is a nitric oxide synthase species found in

neural tissue in physiological conditions. Especially in situations of neuronal damage and neurodegeneration like spinal cord ischemia, increasing values are observed in nNOS expression.

Nuclear factor kappa  $\beta$  (NF $\kappa$ B) is a rarely active transcription factor in normal cells. In situations with increased free oxygen radicals like inflammatory situations, nuclear factor kappa  $\beta$  (NF $\kappa$ B) is activated causing tissue damage.

Based on this, spinal cord samples taken from experimental groups were immunohistochemically assessed at tissue level for caspase 3, nNOS and NF $\kappa$ B expression to evaluate changes in apoptotic death, cerebral damage and inflammation in ischemic spinal cord tissue due to ozone treatment.

#### **Immunohistochemistry for caspase 3, NF $\kappa$ B and nNos**

For immunohistochemical evaluation, the slides were labeled with caspase 3, NF $\kappa$ B, and nNos primary antibodies. The sections were deparaffinized and rehydrated. Citrate buffer (pH=6.0) was used for antigen retrieval in microwave for 20 minutes. Then 3 % hydrogen peroxide in methanol was used to block endogenous peroxidase activity for 12 minutes. After blocking, the sections were incubated with caspase 3 (1:100 dilution, MA116843, Thermo Scientific), NF $\kappa$ B (p65 (1:150 dilution, RB-1638-P1, Thermo Scientific) and nNos (1:100 dilution, PA3-032A, Thermo Scientific) primary antibodies overnight at 4 °C. Then sections were incubated with biotinylated secondary antibody (Anti-polyvalent HRP, Labvision Corp, Fremont, CA) according to the manufacturer's protocol and sections were visualized by AEC kit (Labvision Corp, Fremont, CA) for the chromogen. After counterstaining with Mayer's hematoxylin, slides were mounted with water-based mounting medium and evaluated under a light microscope with an image analysis system (NIS Elements Nikon, Japan). In the immunohistochemical evaluation, caspase 3, NF $\kappa$ B, and nNos immunopositive cells were counted in gray matter in spinal cord samples. Then samples were statistically analyzed.

#### **Statistical Analysis**

Results were analyzed with one-way analysis of variance (ANOVA) using SPSS 21.0 software (SPSS Inc., USA). Differences between the groups were obtained using the Tukey test. Statistical significance was accepted as  $p < 0.05$ . All data are given as mean  $\pm$  standard deviation (SD) for each group.

## **Results**

### **Histopathological Results**

#### **Hematoxylin-Eosin and Toluidin blue staining**

Medulla spinalis samples were fixed in 10 % neutral formalin. After fixation, samples were subjected to routine tissue processing and then samples were embedded in paraffin. Five  $\mu$ m sections were placed on classic and poly-lysine-coated slides. Hematoxylin- Eosin (H&E) and toluidine blue staining were performed. For toluidine blue staining, firstly sections were deparaffinized, then rehydrated and rinsed with distilled water. The sections were stained with 1 % toluidine blue for 2.5 minutes. After staining, the sections were dehydrated with two different 96 % ethanol. Lastly, the slides were cleared in xylene and mounted with entellan H&E and toluidine blue staining was used for evaluation of degenerated neurons, vascularization, and infiltration for each group.

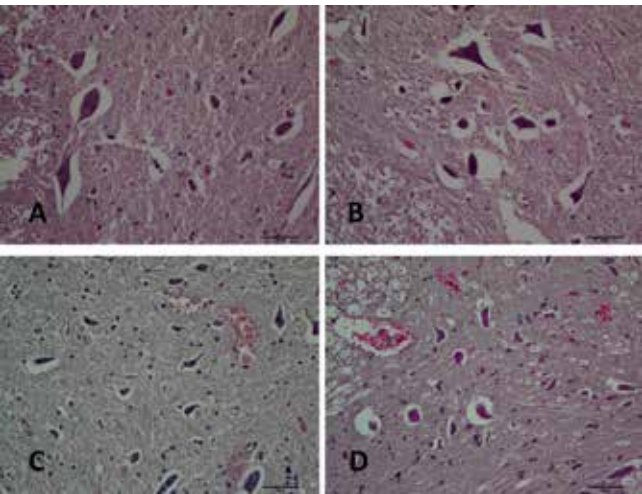
### **Biochemical Estimation Results**

When data obtained from the biochemical analysis are inves-

tigated (Table 1) in the groups with induced ischemia, the expected reduction in SOD, CAT, and GPX enzyme activities are observed and an increase in MPO activity is observed. The statistical difference between the ozone administered groups and the control group was significant ( $p < 0.05$ ). When the ischemia+ozone group was compared with the ischemia group, the results were significant and a statistical difference is observed ( $p < 0.05$ ). When GPX values in the group with ischemia-induced were investigated, the enzyme activity values were very low. A serious increase was observed in the treatment ozone administered group ( $p < 0.05$ ).

**H&E and Toluidine Blue Staining Results**

In the control group, neuronal and vascular structures were assessed to have normal morphology (Figure 1A-2A). There was nearly normal morphology together with very little increase in degenerated neurons in the ozone group (Figure 1B-2B). In the ischemia group, vascularization and infiltration were increased (Figure 1C) and also the number of degenerated neurons was observed as an increased number in gray matter after ischemia (Figure 2C). Ozone treatment partially protected neurons from ischemic injury. The number of degenerated neurons declined in the ischemia+ozone group (Figure 1D-2D).

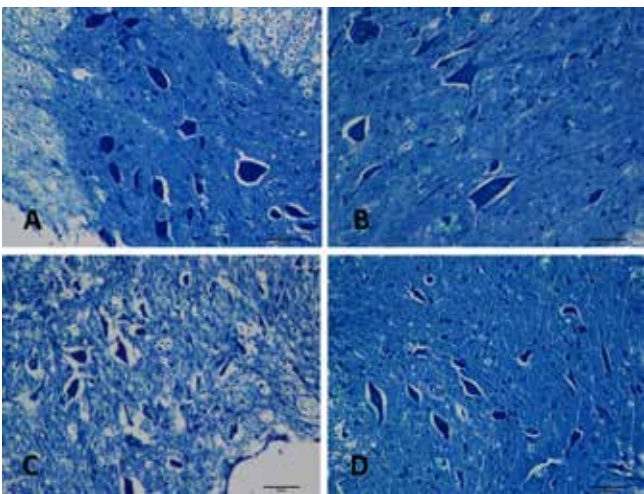


**Figure 1.** Representative sections of spinal cords in gray matter stained with H&E (X200).

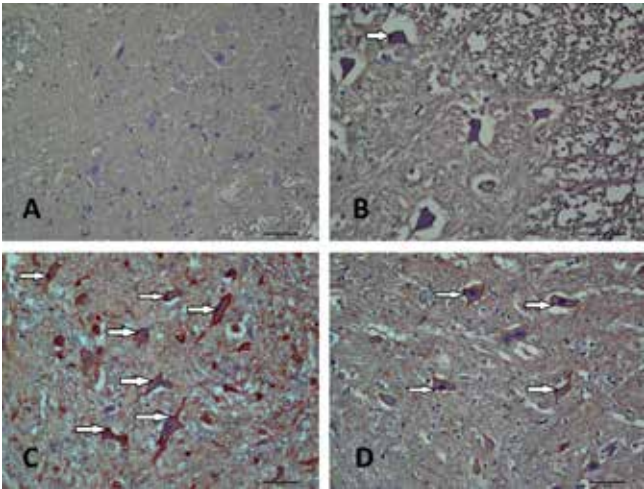
Normal neurons exhibited a fine granular cytoplasm, while degenerated neurons were defined by the presence of cytoplasmic shrinkage with a diffuse cytoplasm. (A) Control group: showing normal parenchyme and viable neurons. (B) Ozone group: showing nearly normal image like control group. (C) Ischemia group: showing increased vascularization, infiltrative cells and degenerated neurons with darkly stained and shrunken cytoplasm in the gray matter. (D) Ischemia+ozone group showing increased vascularization, but motor neurons were less affected than ischemia.

**Caspase 3, NFkB, and nNOS Immunohistochemistry**

In the control group, according to results of immunohistochemistry, immunopositive neurons were rarely observed in motor neurons by immunostaining with caspase 3, NFkB, and nNOS (Table 2, Figure 3A-4A-5A, respectively). In the ozone group, few neurons were stained with these antibodies (Figure 3B-4B-5B), but there was no statistically significant difference com-



**Figure 2.** Representative toluidine blue stained sections from the experimental groups (X200). (A) In the control group, motor neurons showed regular nuclei lightly stained, and Nissl bodies in the cytoplasm. (B) In the ozone group, motor neurons were viable mostly like control group. (C) In the ischemia group, there were degenerated neurons consistent with the surrounding tissue infarcts. (D) Ischemia+ozone group showed less infarct area and neurons were less affected by ischemia.



**Figure 3.** Representative images of caspase 3 immunostaining in the experimental groups (X200). Arrows refer to caspase 3 positivity. (A) In the control group, neurons showed few caspase 3 staining. (B) In the ozone group, a small amount of caspase-3 positive neurons were observed. (C) In the ischemia group, a significantly increased number of caspase 3 positivity was observed in neurons compared to controls. (D) In the ozone-treated ischemia group, caspase 3 positivity was visible in some neurons, but the number of caspase 3 positive cells was lower than that in the ischemia group.

pared with the control group. Caspase 3, NFkB, and nNOS immunoreactivity were increased in the neurons after ischemia. When compared with the control group, there was a significant increase in caspase 3 (Figure 3C), NFkB (Figure 4C), and nNOS

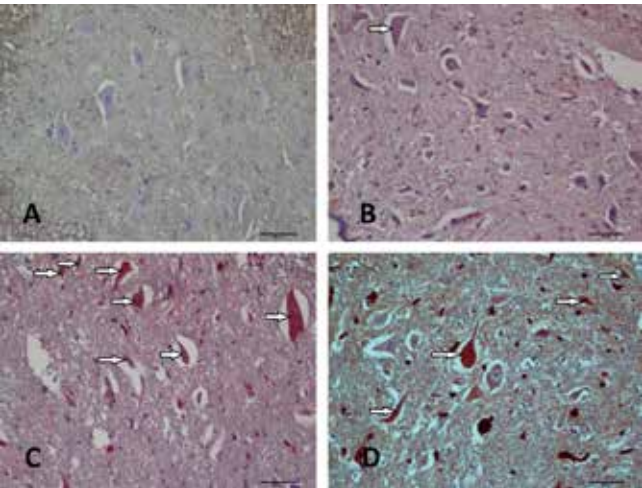
**Table 1.** Superoxide dismutase (SOD), catalase (CAT), glutathione peroxidase (GPX), myeloperoxidase (MPO) activity and malondialdehyde (MDA) levels in rabbit spinal cord tissue.

Groups	SOD (U.ml <sup>-1</sup> .mg protein <sup>-1</sup> )	CAT (U.ml <sup>-1</sup> .mg protein <sup>-1</sup> )	GPX (U.ml <sup>-1</sup> .mg protein <sup>-1</sup> )	MPO (mU.ml <sup>-1</sup> .mg protein <sup>-1</sup> )	MDA (μmole. ml <sup>-1</sup> .mg protein <sup>-1</sup> )
Control	7.20±0.84	25.12±2.08	38.77±5.04	16.73±1.69	19.60±3.77
Ozone	6.58±0.93	28.55±2.56	34.57±3.33	22.94±1.75	22.58±2.18
IAACC (Sham)	3.29±0.47	13.99±1.10	1.98±0.76	33.13±2.35	29.53±3.95
IAACC + Ozone	6.25±0.92	26.31±3.81	32.73±3.45	25.75±4.26	20.64±3.02

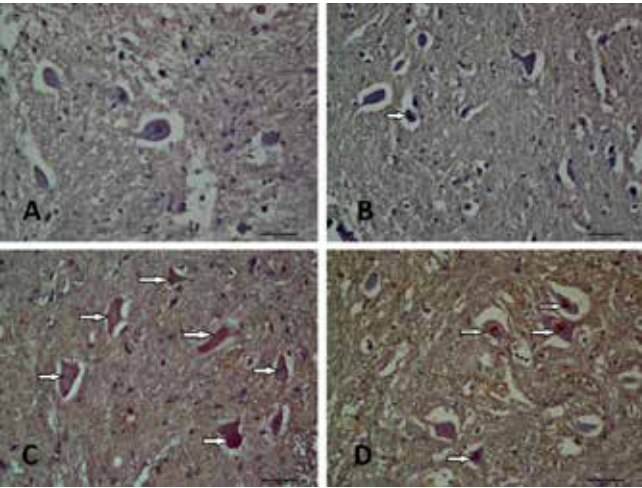


**Table 2.** Histopathological evaluation of the stainings in the experimental groups. The values are presented as mean ± SD. In each line, the difference between the means with the same letters is significant (p<0.05).

	Control	Ozone	Ischemia	Ischemia+ozone
Degenerated neuron number	4±1,54	9±1,41	53±13,38	32,33±11,41
Vascularization	0,33±0,51	0,50±0,54	1,83±0,40	1,33±0,81
Infiltration	0,33±0,51	0,66±0,51	2,33±0,81	1,50±0,54
Caspase 3 immunopositive cells	2,83±1,16	8,33±1,21	31,16±4,99	19,16±4,53
NFkB immunopositive cells	3,83±0,75	10,66±1,86	42,16±11,05	23,16±3,97
nNOS immunopositive cells	2,83±0,75	6,16±2,22	27±6,54	17,83±3,43



**Figure 4.** Representative images of NFkB immunostaining in the experimental groups (X200). Arrows refer to NFkB positive staining in the motor neurons. (A) Neurons showed few NFkB staining in the control group. (B) A small number of NFkB positive neurons were observed in the ozone group. (C) In the ischemia group, NFkB immunopositivity were increased compared to others. (D) Ozone treated ischemia group revealed lesser NFkB immunopositivity than ischemia group.



**Figure 5.** Representative images of nNOS immunostaining in the experimental groups (X200). Arrows refer to nNOS positive staining in the motor neurons. (A) In the control group, few neurons revealed nNOS positive staining. (B) In the ozone group, a small number of nNOS positive neurons were observed. (C) In the ischemia group, increased number of nNOS positivity was observed. (D) nNOS positivity was visible in some neurons in the ozone treatment group, but the number of nNOS positive cells was lower than the ischemia group.

(Figure 5C) immunoreactivity in the ischemia group. In the ozone treated ischemia group immunopositivity for all these

markers caspase 3 (Figure 3D), NFkB (Figure 4D) and nNOS (Figure 5D) were observed to diminish in neurons compared with the ischemia group.

Discussion

Ozone (O3) is a molecule carrying three oxygen atoms forming as a result of exposure of oxygen to high energy electric currents and ultraviolet (UV) light in nature. It is found as a gas at room temperature. It is colorless and has a characteristic smell. As ozone has a high degree of oxidation strength, it is called “active oxygen” in medicine. Due to its ability to increase blood circulation, it is used for treatment, not just of disorders related to circulation, but as an aid to the renewal of organic functions disrupted by many diseases. After ozone administration, it is known to stimulate erythrocyte metabolism increasing the oxygen carrying capacity of hemoglobin and as a result of the amount of oxygen in tissues. Again hemoglobin with larger erythrocyte surfaces carrying excess oxygen encountering ozone can rapidly reach the required region of the body [9]. Ozone has no side effects on therapeutic ratios of 10-80 ug/ml dose intervals and additionally the same ratio is reported to have no negative side effects on either erythrocyte or leukocyte functions. Ozone may be administered to the body with methods such as insufflation, intraarticular injection, major or minor auto-hemotherapy. Ozone therapy activates the antioxidant system affecting glycemia levels. There are studies showing that ozone normalizes organic peroxide levels preventing oxidative stress [10]. SOD detoxifies O2 to H2O2, which is then scavenged by peroxisomal catalase. In other words, H2O2 cannot be easily scavenged during ischemia due to the lower SOD activity [11]. An increase in lipid peroxidation may lead to the release of mitochondrial matrix enzymes as well as lysosomal proteolytic enzymes in the cytoplasm. In this situation, intracellular proteolysis and cellular destruction are increased [12]. MDA is the basic product of lipid peroxidation and is one of the most sensitive indicators of lipid peroxidation. The reperfusion period is relatively responsive to lipid peroxidation. An increase in MDA concentration indicates the degree of lipid peroxidation, which depends on oxidative stress levels in tissue [13]. nNOS is the predominant source of NO in neurons and localizes in the synaptic spaces. Moreover, nNOS has been found in astrocytes and in the adventitia of rat brain vessels. nNOS has been implicated in the modulation of physiological functions such as learning, memory, and neurogenesis as well as being involved in a number of human diseases [14]. Autonomic, endocrine, metabolic and immunological responses to harmful stimuli aiming to provide and sustain homeostasis of the body may be assessed as stress responses. Neutrophils activated by tissue destruction release some enzymes like myeloperoxidase, acid phosphatase, and elastase. During the inflammatory response, there are changes in the ratio of leukocytes in circulation. Hypoxia occurring in situations of spinal cord ischemia may be seen biochemically due to acidosis, free radical damage and membrane disruption [15]. Medical ozone is a chemical agent that consists of three oxygen atoms and has antioxidant, angiogenic and vasodilator effects. Ozone maintains cellular antioxidant systems including glutathione, SOD and enzymatic reactions also preparing the host to confront the pathophysiologic conditions mediated by oxidative stress with repetitive doses. The dose and the method of administration are important for antioxidant efficiency of ozone [16].

Ozone is one of the most controversial gases because it is useful in the stratosphere to block UV radiation, but toxic in the troposphere during chronic air inhalation. Contrary to the old concept that ozone is always toxic, a comparative analysis of ozone levels in lungs compared to blood has fully clarified the possibility of using ozone as a therapeutic agent provided that dosages are not too high in the blood to affect antioxidant capacity [17].

Ozone, when used within the appropriate therapeutic window, is absolutely safe and more effective than many other medications in various abnormalities such as vascular diseases, infected wounds, chronic skin ulcers, initial gangrene, burns and others. The mechanisms of ozone action have been clarified during the last two decades and include improvement in blood circulation and oxygen delivery to damaged tissues, reduction of inflammatory processes and chronic oxidative stress, enhancement of general metabolism, up-regulation of the cellular antioxidant enzyme activity, activation of immune systems and release of growth factors [18].

### Conclusion

Additionally, studies have shown that in normal organisms ozone has anti-inflammatory properties and increases the oxygen carrying capacity of hemoglobin. Within the scope of our study, we aimed to research how ozone administered by rectal insufflation under general anesthesia to rabbits affected superoxide dismutase (SOD), catalase (CAT), glutathione peroxidase (GPX), myeloperoxidase (MPO) activities and malondialdehyde (MDA) levels. Additionally, tissue healing was evaluated histopathologically and immunohistochemically. It is considered that the obtained data will provide findings beneficial to humans. The present investigation has a key impact on its suggestion that ozone could be developed for future applications in preventing and treating spinal ischemia. Ultrastructural studies are required to extend these observations.

### Scientific Responsibility Statement

*The authors declare that they are responsible for the article's scientific content including study design, data collection, analysis and interpretation, writing, some of the main line, or all of the preparation and scientific review of the contents and approval of the final version of the article.*

### Animal and human rights statement

*All procedures performed in this study were in accordance with the ethical standards of the institutional and/or national research committee and with the 1964 Helsinki declaration and its later amendments or comparable ethical standards. No animal or human studies were carried out by the authors for this article.*

**Funding:** This study was supported by Çanakkale Onsekiz Mart University Scientific Research Projects with project number TSA-2015-392.

### Conflict of interest

*None of the authors received any type of financial support that could be considered potential conflict of interest regarding the manuscript or its submission.*

### References

1. Bocci, V. Scientific and medical aspects of ozone therapy. State of the art. Archives of Medical Research. 2006; 37: 425-35.
2. Bocci, V. Is it true that ozone is always toxic? The end of a dogma. Toxicology and Applied Pharmacology. 2006; 216 (3): 493-504.
3. Bocci V. Can ozonotherapy be performed if the biochemistry of the process cannot be controlled? Archives of Medical Research. 2007; 38: 584-5.
4. Braugher JM, Hall ED. Central nervous system trauma and stroke: biochemical considerations for oxygen radical formation and lipid peroxidation. Free Radic Biol Med. 1989; 6: 289-301.
5. Dall' Olio M, Princiotta C, Cirillo L, Budai C, de Santis F, Bartolini S, et al. Oxygen-ozone therapy for herniated lumbar disc in patients with subacute partial motor weakness due to nerve root compression. Interv Neuroradiol. 2014; 20(5): 547-54.
6. Gutsaeva DR, Carraway MS, Suliman HB, Demchenko IT, Shitara H, Yonekawa H, et al. Transient hypoxia stimulates mitochondrial biogenesis in brain subcortex

- by a neuronal nitric oxide synthase-dependent mechanism. J Neurosci. 2008; 28: 2015-24.
7. Gutteridge JM. Lipid peroxidation and antioxidants as biomarkers of tissue damage. Clin Chem. 1995; 41: 1819-28.
8. Hernandez FA. To what extent does ozone therapy need a real biochemical control system? Assessment and importance of oxidative stress. Archives of Medical Research. 2007; 38: 571-8.
9. Kesik V, Yüksel R, Yiğit N, Saldır M, Karabacak E, Erdem G, et al. Ozone Ameliorates Doxorubicin-Induced Skin Necrosis- results from an animal model. Int J Low Extrem Wounds. 2015; 18: 17-20.
10. Li LJ, Yang YG, Zhang ZL, Nie SF, Li Z, Li F, et al. Protective effects of medical ozone combined with traditional Chinese medicine against chemically-induced hepatic injury in dogs. World Journal Gastroenterology. 2007; 13(45): 5989-94.
11. Lu J, Xiao WP, Geng ZL, Liu D, Wang YF. Effect of aloe polysaccharides pretreatment on the cerebral inflammatory response and lipid peroxidation in severe hemorrhagic shock rats first entering high altitude. Zhonghua Wai Ke Za Zhi. 2012; 50: 655-8.
12. Lu W, Li YH, He XF. Treatment of large lumbar disc herniation with percutaneous ozone injection via the posterior-lateral route and inner margin of the facet joint. World Journal of Radiology. 2010; 2(3): 109-12.
13. Mehta J, Dinerman J, Mehta P. Neutrophil function in ischemic heart disease. Circulation. 1989; 79: 549-56.
14. Nogales C, Ferrari P, Kantarovich E. Ozone therapy in medicine. The Journal of Contemporary Dental Practice. 2008; 9(4): 75-84.
15. Onal O, Yetişir F, Sarer AE, Zeybek ND, Onal CO, Yürekli B, et al. Prophylactic Ozone Administration Reduces Intestinal Mucosa Injury Induced by Intestinal Ischemia- Reperfusion in the Rat. Mediators Inflamm. 2015; 79: 17-20.
16. Tylicki L, Biedunkiewicz B, Rachon D. No effects of ozonated autohemotherapy on inflammation response in hemodialyzed patients. Mediators of Inflammation. 2004; 13: 377-80.
17. Viebahn Haensler R. Uygulama biçimleri ve kullanım alanları. Tedavi uygulamaları. Balkan B çeviri editörü. Ozonun Tıpta Kullanımı. 1.Baskı. İstanbul: Medikal Ozon Oksijen Derneği; 2005. 1: p.53-65.
18. Zhou L, Zhu DY. Neuronal nitric oxide synthase: structure, subcellular localization, regulation and clinical implications. Nitric Oxide. 2009; 20: 223-30.

### How to cite this article:

Akman T. The ameliorative effect of ozone therapy on spinal cord ischemia in rabbits. Ann Clin Anal Med 2020;11(3):221-226